



# A double-blinded, placebo-controlled trial to determine the role of a combination regimen of systemic and topical green tea in UV protection and the improvement of skin appearance

Annie Chiu, BS<sup>1</sup>; Wingfield E. Rehmus, MD<sup>1</sup>; Dale Kern, BS<sup>2</sup>; Sabine Kohler, MD<sup>1</sup>; Alexa B. Kimball, MD, MPH<sup>1</sup>  
*Stanford University<sup>1</sup>, Nu Skin International, Inc.<sup>2</sup>*

## Background

Green tea extracts have recently gained popularity as an ingredient to treat aging skin, both in the form of topical skin care preparations and as a nutritional oral supplement with purported benefits for the skin. The polyphenolic compounds found in green teas have significant antioxidant and anti-inflammatory activities in-vitro, and mouse models have shown that these extracts can help mediate ultraviolet (UV) radiation damage in both the topical and oral forms of supplementation. Despite the recent claims made in the popular media, whether these protective effects will have any clinical significance on aging and UV damaged human skin remains a largely unanswered question.

## Objective

To evaluate the effects of a combination regimen of topical green tea cream and green tea oral supplementation on the clinical and histological characteristics of photoaging.



## Methods & Materials

40 healthy women with skin age 2-3 on the Glogau scale of photoaging, and Fitzpatrick skin type I-III, were randomized to:

### Treatment group:

- 10% green tea extract cream
- Green tea supplement 300mg bid
- Cleanser and sunscreen

### Placebo group:

- Placebo cream
- Placebo supplement
- Cleanser and sunscreen

Subjects were asked to use their regimens for 8 weeks. 35 subjects completed the study. Clinical grading and histological grading based on skin biopsies were conducted at baseline and at the end of the eight week treatment period.

Clinical grading was based on

- Fine wrinkling
- Tactile roughness
- Visual dryness
- Coarse rhytids
- Telangiectasias
- Skin laxity/tone
- Pigmentation
- Sallowess/yellowing
- Actinic lentiginos
- Actinic keratoses
- Global evaluation

Histological grading was based

- Epidermal thickness
- Perivascular inflammation
- Dermal collagen
- Solar elastosis
- Elastic tissue content
- Melanin content

## Results

Histological grading of 4mm punch biopsies of the skin showed a significant improvement in elastic tissue content for the green tea treated group when compared to placebo (Figure 1).

No significant differences were found on clinical grading between the green tea treated and placebo groups after 8 weeks.

Figure 1

Elastic tissue content was graded from a scale of -2 to +2.

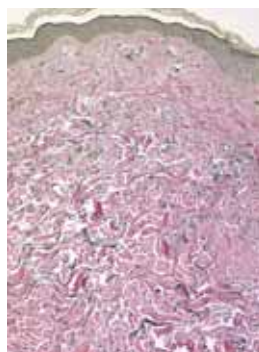

- +1/+2 = More elastic tissue
- 0 = Unchanged
- 1/-2 = Less elastic tissue

Treated:

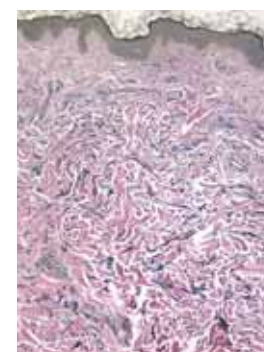
Mean= 0.2 (SD=1.01)

Placebo:

Mean= -0.55 (SD=0.85)



Baseline



8 weeks

## Conclusions

Green tea polyphenols have been recently touted by the skin care industry to be beneficial in protecting human skin from the cutaneous signs of photoaging. After eight weeks of both topical and oral supplementation, histologic grading found improvement in elastic tissue content when compared to placebo. However, clinically significant changes could not be seen after eight weeks, suggesting that clinically visible improvements on the skin may take longer supplementation to achieve.

## References

1. Katiyar SK, Ahmad N, Mukhtar H: Green tea and skin. Arch Dermatol 2000;136:989-994.
2. Katiyar SK, Elmets CA: Green tea polyphenolic antioxidants and skin photoprotection (Review). Int J Oncol 2001;18:1307-1313.
3. Elmets CA, Singh D, Tubesing K, Matsui M, Katiyar S, Mukhtar H: Cutaneous photoprotection from ultraviolet injury by green tea polyphenols. J Am Acad Dermatol 2001;44:425-432.
4. Agarwal R, Katiyar SK, Khan SG, Mukhtar H: Protection against ultraviolet B radiation-induced effects in the skin of SKH-1 hairless mice by a polyphenolic fraction isolated from green tea. Photochem Photobiol 1993;58:695-700.

This study was funded by a grant from Nu Skin International Inc.